

Dendritic cell leukemia in patient with extranodal nk/t-cell nasal type lymphoma: Case report

Eduardo JM¹, Salgues AC¹, de Oliveira VH², Guiguer IC², Casati MF², Barbosa AA², Matushita CM², Pallotta R³, Borducchi DM⁴

| Resumo

A leucemia de células dendríticas é uma neoplasia hematológica rara, altamente agressiva e de prognóstico reservado. Esse relato aborda o caso de uma paciente jovem, do sexo feminino, com apresentação inicial de Linfoma Não-Hodgkin células T NK extranodal e evolução para leucemia de células dendríticas. O quadro em questão foi atípico, com idade de apresentação precoce e ausência de lesões cutâneas.

| Abstract

The dendritic cell leukemia is a rare disease, with aggressive behavior and reserved prognosis. This report approaches the case of a female young patient who was diagnosed with nasal NK/T-cell lymphoma evolving to a dendritic cell leukemia. This case reported was atypical, with early appearance and absence of cutaneous lesions.

| Introduction

The dendritic cell leukemia is a rare hematological neoplasia, which is highly aggressive. It represents less than 1% of the acute leukemias. The male sex predominates and the higher incidence of the disease occurs over 66 years of age. It is characterized by the expression of CD4+ and CD56+, in the absence of other lymphoid, natural killer (NK) or myeloid antigens. The clinical findings of dendritic cell leukemia include, in general, cutaneous lesions followed by tumoural dissemination and bone marrow involvement. There is an excellent chemosensitivity at the beginning, but also an early relapse and evolution to death in most cases.

| Case Report

E.S., 32-year-old woman, was diagnosed with nasal NK/T-cell lymphoma in February, 2013. A bone marrow biopsy and conventional imaging methods (chest and abdomen computed tomography) did not show any evidence of neoplastic infiltration. The treatment began with radiotherapy (45 Gy), associated with cisplatin for 4 weeks, followed by a VIPD scheme chemotherapy for 4 cycles, the last one in June, 2013. Then, there was a complete remission of the tumor. However, in December, 2013, the patient returned complaining about a pain on the medial area of the left upper limb, a left neck pain, headache and nausea. The liquor analysis showed immunophenotyping compatible with anomalous lymphoid cells infiltration with the following expressions: CD4, CD56 and HLA-DR. At that moment, the diagnosis of the disease's relapse with infiltration of the central nervous system was confirmed. The treatment with the MADIT scheme for 4 weeks started, and the last cycle occurred in January, 2014. The skull and cervical spine MRI did not demonstrate lesions. The bone

| Palavras-chave

Leucemia, Células Dendríticas, Linfoma Extranodal de Células T-NK, Estudos de Casos

| Keywords

Leukemia, Dendritic Cells, Lymphoma, Extranodal NK-T-Cell, Case Studies

¹ Hospital do Servidor Público Municipal, São Paulo, SP, Brazil

² Faculdade de Medicina do ABC, Santo André, SP, Brazil

³ Associate Professor in Hematology and Oncology Division, Faculdade de Medicina do ABC, Santo André, SP, Brazil

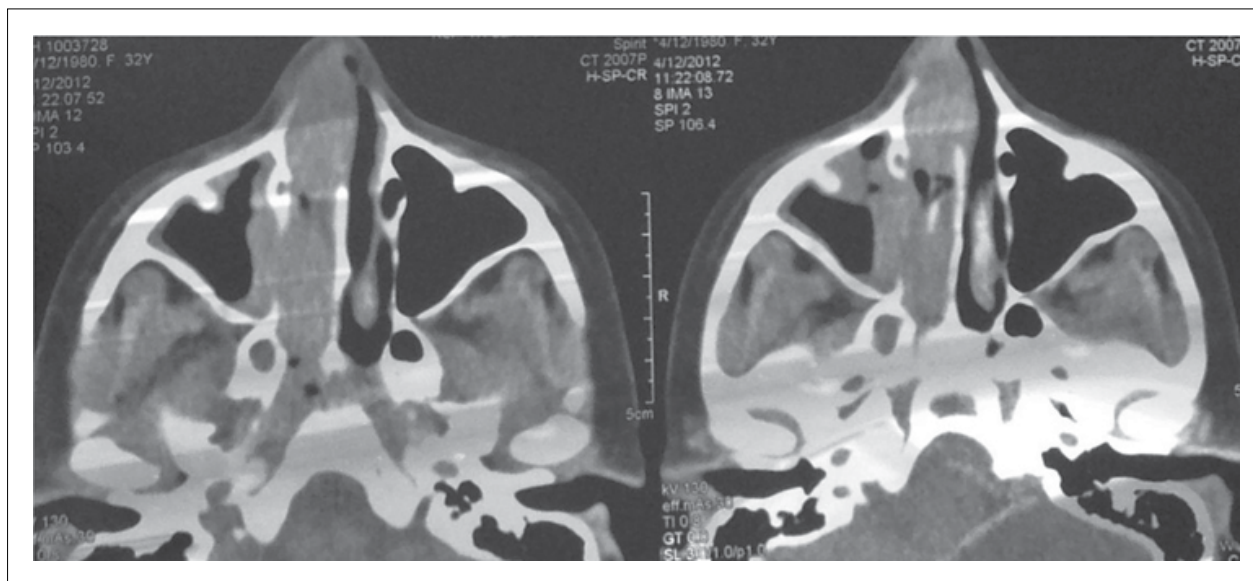
⁴ Assistant Professor in Hematology and Oncology Division, Faculdade de Medicina do ABC, Santo André, SP, Brazil

The case report should be attributed to the following institutions and/or departments:

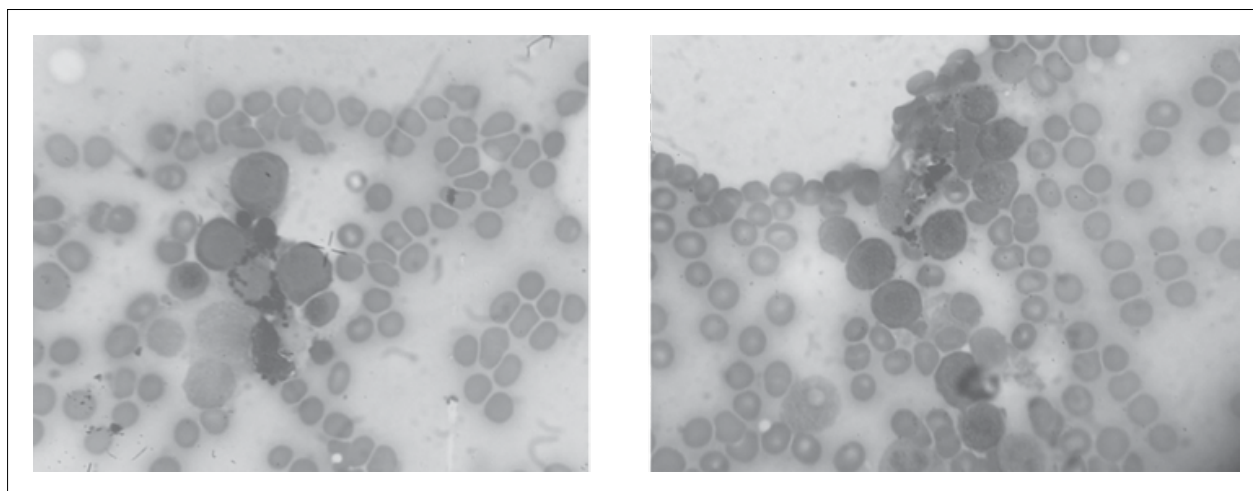
- Hospital do Servidor Público Municipal de São Paulo
- Sociedade Acadêmica de Estudos em Hematologia (SAEH) da Faculdade de Medicina do ABC
- Centro de Estudos e Pesquisas em Hematologia e Oncologia (CEPHO)
- Faculdade de Medicina do ABC

Autor correspondente:

Isabella Cherkezian Guiguer, MS
Rua Bahia 430 AP 21, Higienópolis,
São Paulo-SP
Phone number: +55 11 97551-6888
E-mail: isacherk@hotmail.com



Figures 1 and 2. Initial presentation, nasal T/NK cells lymphoma.



Figures 3 and 4. Bone marrow examination with the presence of blasts

marrow was hypocellular and normomaturative (about 40 %). In March, 2014, the patient returned with epistaxis, without evidences of cutaneous lesions. The CBC showed a pancytopenia, and the bone marrow examination was compatible with an acute leucosis (60 % of blasts). The immunophenotyping with CD4+, CD56+, CD123, HLA-DR of strong intensity on the anomalous cells, was highly suggestive of a blasticplasmacytoid dendritic cells leukemia. At the time, a chemotherapy with HyperCVAD was initiated. After the first cycle of the

new treatment, the bone marrow examination showed a normocellular marrow and a partial remission (6.8% of blasts). Minimal residual disease was detected at the immunophenotyping. The patient evolved to a febrile neutropenia and death in July, 2014.

| Discussion

The malignancies CD4+ and CD56+ are rare haematopoietic neoplasias, recently connected to the lymphop-

plasmacytoid dendritic cells. The few cases described are typically presented with cutaneous lesions, followed by tumoral dissemination with a generally aggressive course and progression to death. The diagnosis is based mainly on the immunophenotypic profile of the cells. There are high rates of remission and relapse. The rarity of this disease is responsible for the uncertainty about the best therapeutic conduct. In the case presented above, some clinical and biological characteristics were not similar to the ones described in literature: age of appearance and absence of cutaneous lesions. These differences corroborated by the description of other similar cases in literature show that there is a clinical biological heterogeneity within this neoplastic entity, in spite of its rarity.

| Conclusion

The dendritic cell leukemia is an infrequent disease, with aggressive behavior and reserved prognosis.

Eduardo, J.M. *et al.* Dendritic cell leukemia in patient with extranodal nk/t-cell nasal type lymphoma: case report. **Clinical Oncology Letters**. 2016;2(2):19-21.

| References

1. Pilichowska ME, Fleming MD, Pinkus JL & Pinkus GS. CD4+/CD56+ Hematodermic Neoplasm ("Blastic Natural Killer Cell Lymphoma"). *American journal of clinical pathology*. 2007, 128(3), 445-453.
2. Prochaska L, Dakhil C, Mathur S. Blastic Plasmacytoid Dendritic Cell Neoplasm: A Rapidly Progressive and Fatal Disease without Aggressive Intervention. *Med Insights Case Rep*. 2013; 6: 201–204.
3. UpToDate [www.uptodate.com]. UpToDate, Post TW (Ed), UpToDate, Waltham, MA. (Accessed on May 04, 2014). Sandeep Gurbuxani, MBBS. Blasticplasmacytoid dendritic cell neoplasm. Disponivel em: <http://www.uptodate.com/contents/blastic-plasmacytoid-dendritic-cell-neoplasm>.